



STUDY OF THE USES AND RESULTS OF PLATELET RICH PLASMA IN CHRONIC NON HEALING WOUNDS

Dr. Suyash Singodiya, *Dr. Moolchand Prajapat, Dr. Divyata Vasa

Third year Resident, Dept of General Surgery, Sheth LG hospital, Ahmedabad.

Assistant Professor, Dept of Burns and Plastic Surgery, Sheth LG hospital, Ahmedabad.
prajapat1938@gmail.com

Intern, Sheth LG hospital, Ahmedabad)

Abstract

Introduction: Platelet-rich Plasma (PRP) is an autologous product, made from anticoagulated blood that has been centrifuged to increase the concentration of platelets compared to whole blood. Chronic cutaneous wounds are frequent problem in developing countries & are often difficult to heal because they lack the growth factors necessary for the healing process & are frequently complicated by super infection. Conventional therapies such as dressings, surgical debridement, and even skin graft cannot provide satisfactory healing since these treatments are not able to provide enough necessary growth factors to modulate the healing process. PRP has become a valuable adjunct in wound healing in plastic surgery. Each growth factor has the capability to induce a unique response in the enhancement of healing thus accelerating and enhancing the natural wound healing of the body. The aim of this study is to assess the effects of platelet-rich plasma (PRP) in chronic non healing wounds. **Methods:** This prospective study included patients attending outpatient and inpatient facility of Burns & Plastic surgery Department., 17 patients with Chronic ulcers not healing after 6 weeks' treatment with dressing or other adjuvant, etiology chronic venous ulcers, post burn ulcers, post traumatic ulcers, diabetic ulcers, tropical ulcers, etc. were included. **Results:** With 100% healing of chronic ulcers after PRP infiltration at margins of ulcer, it is found that PRP is a good modality for treatment of chronic ulcer which is reluctant to heal by dressings for long duration. **Conclusion:** The study was successfully completed during the period of October 2013 to February 2016. Applicability and Efficacy of PRP was found in variety of chronic ulcers due to varicose vein, pressure sore, post burn or trauma. With 100% healing of chronic ulcers after PRP injection, with no complication of PRP, it can be satisfactorily used in patients with chronic wounds.

Keywords: Platelet rich plasma, chronic ulcers, non-healings wound.

INTRODUCTION

Platelet-rich Plasma (PRP) is an autologous product, made from anticoagulated blood that has been centrifuged to increase the concentration of platelets compared to whole blood. It contains an autologous concentration of human platelets in a small volume of plasma, containing seven fundamental protein growth factors (PDGF) proved to be actively secreted by platelets to initiate all wound healing, angiogenesis & tissue remodeling. Platelets are the first cells to arrive at an injury site to begin hemostasis through cell membrane adherence, aggregation, and clot formation. During degranulation, they release growth factors, cytokines, and bioactive proteins that enhance and regulate tissue healing. PRP has become a valuable adjunct in wound healing in plastic surgery. Each growth factor has the capability to induce a unique response in the enhancement of healing thus accelerating and enhancing the natural wound healing of the body. These growth factors have a positive effect on the recruitment of macrophages, osteoblasts and other precursors, differentiation and activation of fibroblasts, and recruitment and activation of endothelial cells, enhancing angiogenesis. The aim of this study is to assess the effects of platelet-rich plasma (PRP) in chronic non healing wounds.



Figure 1: Timeline of Application of PRP



REVIEW OF LITERATURE

According to Marx et al., Platelet-rich plasma (PRP), also termed autologous platelet gel, plasma rich in growth factors (PRGF), platelet concentrate (PC), is essentially an increased concentration above the base line normal platelets count suspended in a small amount of plasma after centrifugation. PRP is prepared either manually or by the use of automated devices, in a day care setting just prior to the procedure. The process must be carried out under strict aseptic conditions as well as optimum temperature regulations i.e., 20-22°C. In order to inhibit platelet aggregation, it is prepared with an anticoagulant, commonly using anticoagulant citrate dextrose solution formula A (ACD-A) or sodium citrate (3.2%). The platelets need to be sequestered in high concentrations, enough for achieving therapeutic benefit and in a viable state at the same time, so that they can actively secrete their growth factors.

Table no. 1: - Contents of PRP Growth factors & their actions

Growth Factors	Functions
Transforming growth factor – beta	Stimulates undifferentiated mesenchymal cell proliferation Regulates endothelial, fibroblastic & osteoblastic Mitogenesis Regulates collagen synthesis & collagenase secretion Regulates mitogenic effects of other growth factors Stimulates endothelial chemotaxis & angiogenesis Inhibits macrophages & lymphocytes proliferation
Fibroblast Growth factor (FGF)	Promotes growth & differentiation of chondrocytes & Osteoblasts Mitogenetic for mesenchymal cells, chondrocytes & osteoblasts.
Platelet Derived Growth Factor a & b	Mitogenetic for mesenchymal stem cells & osteoblasts. Stimulates chemotaxis & mitogenesis in fibroblasts, glial



(PDGF)	or smooth muscle cells Regulates collagen synthesis & collagenase secretion Stimulates chemotaxis of macrophages & neutrophils
Epidermal Growth Factor (EGF)	Stimulates endothelial chemotaxis & angiogenesis Stimulates epithelial or mesenchymal mitogenesis
Vascular Endothelial Growth Factor(VEGF)	Stimulates mitogenesis for endothelial cells Increases angiogenesis & vascular permeability
Connective Tissue Growth Factor(CTGF)	Promotes angiogenesis Cartilage regeneration Fibrosis & platelet adhesion
Insulin Like Growth Factor 1&2 (ILGF-1 &2)	Enhances bone formation Chemotactic for fibroblast & stimulate protein synthesis
Platelet Factor 4 (PF4)	Stimulates the initial influx of neutrophils into wounds Chemoattractant for fibroblasts
Interleukin 8 (IL-8)	Proinflammatory mediator Recruitment of inflammatory cells
Keratinocytes Growth Factor (KGF)	Promotes endothelial cell growth, migration, adhesion & survival angiogenesis

Being an autologous preparation, PRP is devoid of any serious adverse effects, apart from local injection site reactions like pain or secondary infection or injury to nerves or blood vessels which can be avoided with proper precautions. PRP has no issues regarding transmission of infections such as Hepatitis-B, C or HIV. Scar tissue formation and calcification at the injection site are also possible.

Absolute Contraindications:

- o Platelet dysfunction syndrome
- o Critical thrombocytopenia
- o Hemodynamic instability
- o Septicemia
- o Local infection at the site of the procedure

Relative Contraindications

- o Corticosteroid injection at treatment site within 1 month
- o Systemic use of corticosteroids within 2 weeks
- o Recent fever or illness
- o Cancer- especially hematopoietic or of bone
- o Hemoglobin < 10 g/dl
- o Platelet count < 10⁵/ul.

Chronic cutaneous wounds are frequent problem in developing countries & are often difficult to heal because they lack the growth factors necessary for the healing process & are frequently complicated by super infection. Conventional therapies such as dressings, surgical debridement, and even skin graft cannot provide satisfactory healing since these treatments are not able to provide enough necessary growth factors to modulate the healing process. Patients with chronic ulcers frequently have to undergo long term dressing regimens & repetitive debridement without a definitive outcome. Some commercially available recombinant growth factor products like recombinant PDGF-BB is FDA approved for



treatment of chronic wounds, but its time release delivery is a significant problem because it is liquid & quickly disappears once it has been applied to the wound. Additionally, the product is expensive & most patients can't afford such high cost in developing countries. PRP can be proven to be a feasible treatment option in such cases.

AIMS AND OBJECTIVES

To evaluate the efficacy of PRP in the management of chronic non healing ulcers.

MATERIALS AND METHODS

Source of data and inclusion criteria:

This prospective study included patients attending outpatient and inpatient facility of Burns & Plastic surgery Department of Smt. S.C.L. Municipal Hospital attached to Smt. N.H.L. Municipal Medical College, Ahmedabad from October 2013 to February 2016. After taking informed consent, 17 patients with Chronic ulcers not healing after 6 weeks' treatment with dressing or other adjuvant, etiology chronic venous ulcers, post burn ulcers, post traumatic ulcers, diabetic ulcers, tropical ulcers, etc. were included.

Exclusion Criteria:

- Having Coagulopathy or with history of bleeding disorders.
- Immunocompromised status.
- Platelet count < 150,000/mm³.
- Allergies or hypersensitivity to any drug.
- Patients on anti-coagulant medications
- Patients with active infection at the local site of PRP application
- Patients with keloidal tendency.
- Chronic ulcers with diameter more than 5 cm.
- Patient with complex tendon injury.

Preparation of PRP

PRP is prepared by manual dual spin centrifugation technique. 10 ml of blood is collected from the patient and divided into a 5 ml vacutainer tube with 0.5 ml of trisodium citrate. PRP is obtained using the general purpose tabletop centrifuge, first centrifuging at a 1300 rpm for 10 minutes (light spin) which provide three layers. Upper layer consists of platelets mostly is transferred to another empty tube. Second spin at 2000 rpm for 10 minutes (hard spin) is done which gives two layers. PRP is in lower layer. PRP is extracted and stored in another empty tube. PRP is activated before application by combining with 10% calcium chloride.

The following details were noted:

- Demographic history - name, age, sex, address, contact number, education, marital status, occupation.
- Present disease history
- Past history – any chronic disease like tuberculosis, diabetes mellitus, hypertension, ischemic heart disease, any relevant surgery, any treatment history.
- Past history
- Family history

Examination: Selected patients were thoroughly examined for local disease as described in proforma.

A total of 4-6 sittings were given to each patient at interval of 15 days each, over a total period of 2-3 months where 1 to 2.5ml PRP was injected in each sitting. Also, patients were prescribed antibiotics and analgesics for few days during the course of therapy.

The evaluation and interpretation of results is relatively straight forward. Results were analyzed:

- In the 1–7-day immediate post-injection period to determine swelling, bruising, which subside with time.
- In the relative short term – 3–6-month period.
- In the intermediate term – 6–12-month period & In the long term – 12–24-month period and beyond.

For short-term evaluation, visual examination and descriptive records supported by photographs should suffice. For longer-term evaluation, no recurrence in wound would yield the most objective results, complemented by high-quality standardized photographs, which may be sufficient as a stand-alone evaluation standard.



Medico-Legal Aspects:

The patient had the absolute right to receive enough information about his diagnosis, proposed treatment, prognosis, and possible risks of proposed therapy and alternatives to enable her/him to make a knowledgeable decision. The few minor complications encountered in PRP made this procedure a relatively low risk for litigation.

OBSERVATIONS & RESULTS

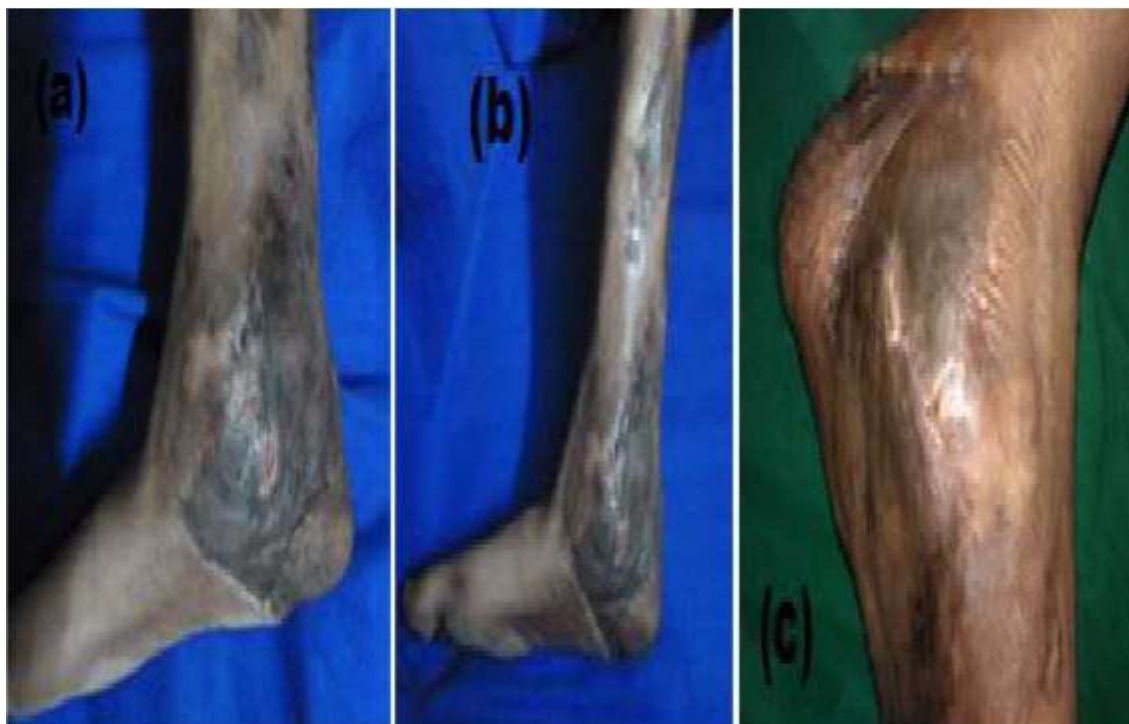
This Series on “Study of Variety of Uses and Their Results of Platelet Rich Plasma in Plastic Surgery” was mainly conducted in Smt. N.H.L. Medical College and Smt. S. C. L. Municipal Hospital, Ahmedabad during the period of October 2013 to February 2016 in the Dept of Burns and Plastic surgery.

In this study the size of chronic ulcer was from 1cm*1 cm smallest to 5cm*4cm largest and duration of chronic ulcer from 1 month to 9 months. All were given multiple sittings from 2 to 5 depending upon progress in form of healing of ulcer and 1 to 2.5ml PRP was injected in each sitting. Maximum of 3 sittings were required by the patient, interval between each sitting being 1-2 weeks. Most of the patients were treated on outpatient basis and were kept under observation for 4 hours to monitor of pain and other minor complaints. Patients in whom other procedures like NPWT or STG were also performed during the PRP sitting were hospitalized for few days depending upon the need ranging from 1 week to 3 weeks. All patients had minor complaints like pain at injection site. No other complication was noted.

With 100% healing of chronic ulcers after PRP infiltration at margins of ulcer, it is found that PRP is a good modality for treatment of chronic ulcer which is reluctant to heal by dressings for long duration.

Clinical Photographs

1. M/38 Rt. Heel area pressure sore in O/C/O STG



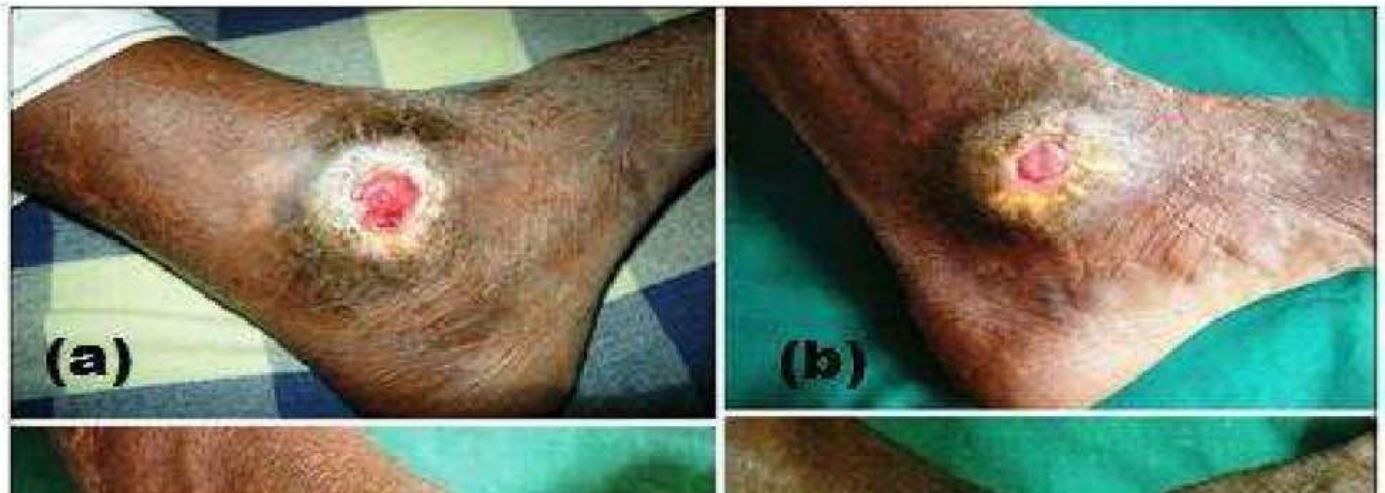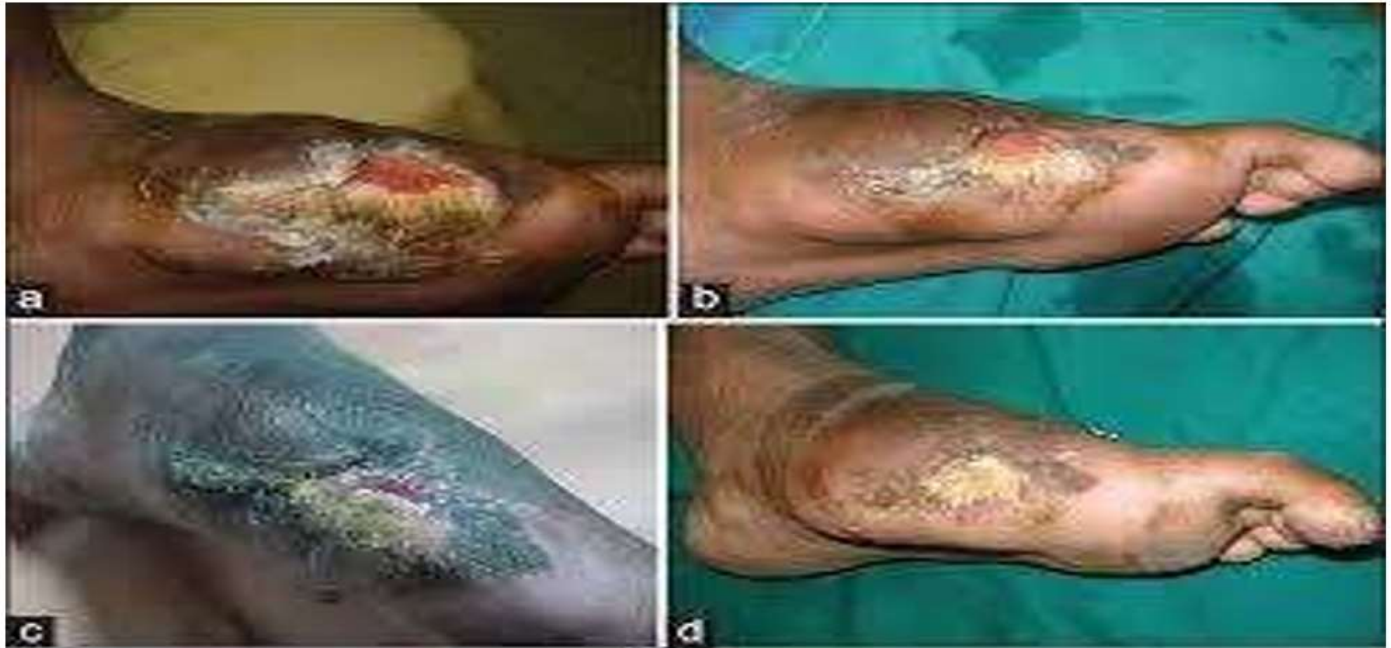(a) On presentation

(b) at 2 weeks

(c) at 4 weeks

2. M/65Rt. Lateral malleolar non healing ulcer

- (a) On presentation
(b) At 2 weeks
(c) At 4 weeks
(d) At 6 weeks



3. M/48 Lt 1st metatarsal head pressure ulcer

- (a) on presentation
- (b) At 2 weeks
- (c) At 4 weeks
- (d) At 6 weeks

DISCUSSION

Platelet-Rich Plasma is an autologous blood component separated from blood after centrifugation. It is rich in growth factors like PDGF, VEGF, TGF etc. The clinical application of PRP is due to it being rich in growth factors. It is autologous in nature, so PRP is free from allergic reactions & transmitted disease.

Platelets play a fundamental role in hemostasis and are a natural source of growth factors. Growth factors, stored within platelet α -granules, include platelet derived growth factor (PDGF), insulin like growth factor (IGF), vascular endothelial growth factor (VEGF), platelet derived angiogenic factor (PDAF), and transforming growth factor beta (TGF- β). PDGF, VEGF & TGF- β are important amongst all. The release of these growth factors is triggered by the activation of platelets that can be initiated by a variety of substances or stimuli such as thrombin, calcium chloride, or collagen. Growth factors



are involved in key stages of wound healing and regenerative processes including chemotaxis, proliferation, differentiation, and angiogenesis.

According to the definition of PRP, it may be assumed that these growth factors are present at increased concentrations in PRP. In addition to growth factors, platelets release numerous other substances (e.g., fibronectin, vitronectin, sphingosine 1-phosphate, etc...) that are important in wound healing. An advantage of PRP over the use of single recombinant human growth factor delivery is the release of multiple growth factors and differentiation factors upon platelet activation. Recently, the morphologic and molecular configuration of PRP was reported, it showed PRP is a fibrin framework over platelets that have the potential to support regenerative matrix. Since PRP contains several growth factors (e.g., PDGF, VEGF, etc...) that are capable to stimulate angiogenesis and increase fibroblast cell differentiation, using PRP to promote soft tissue healing has been proposed. Research showed that PRP and analogous products improve graft adhesion and minimizes micro-movement, providing the most advantageous environment for graft acceptance. It has been also proposed that PRP accelerates wound maturity and epithelialization, hence decreased scar formation. PDGF and epidermal growth factor (EGF) are the main growth factors involved in fibroblast migration, proliferation, and collagen synthesis. Increased concentrations of these growth factors are likely the reason for the accelerated soft tissue wound healing, which is suggested to be at least 2–3 times faster than that of normal. This study showed the applicability of PRP for a wide range of age group. We have tried PRP application in chronic wounds of different etiology and found healing in 100% patients. Based on this research, it can be used in chronic wounds of any etiology with skin loss which are reluctant to heal with dressing only. The follow up period in our study ranged from 6 weeks to 12 months with average follow up period of 12 weeks, during which there was satisfactory healing.

CONCLUSION

The study was successfully completed during the period of October 2013 to February 2016. Applicability and Efficacy of PRP was found in variety of chronic ulcers due to varicose vein, pressure sore, post burn or trauma. With 100% healing of chronic ulcers after PRP injection, with no complication of PRP, it can be satisfactorily used in patients with chronic wounds.

ACKNOWLEDGEMENTS: none

CONFLICTS OF INTEREST: none

FUNDING: Nil

BIBLIOGRAPHY

- Platelet-rich plasma: evidence to support its use. By Marx RE J Oral Maxillofacial Surgery. 2004 Apr; 62(4):489-96.
- Platelet-rich plasma: from basic science to clinical applications. By Foster TE, Puskas BL, Mandelbaum BR, Gerhardt MB, Rodeo SA Am J Sports Med. 2009 Nov; 37(11):2259-72.
- Blood Platelets: Physiology, Pathophysiology, Membrane Receptors, Antiplatelet Principles and Therapy for Atherosclerotic Diseases by Meinrad Gawaz
- Rubin's Pathology: Clinicopathologic Foundations of Medicine Edited by Raphael Rubin, David S. Strayer, Emanuel Rubin, Jay M. McDonald (M.D.)
- Augmenting tendon and ligament repair with platelet-rich plasma (PRP) Yuan, Ting and Zhang, Chang-Qing and Wang, James H-C. (2013) Augmenting tendon and ligament repair with platelet-rich plasma (PRP). M.L.T.J. Muscles, Ligaments and Tendons Journal, 3 (3). pp. 139-149. ISSN 2240-4554
- European Handbook of Dermatological Treatments Edited by Andreas Katsambas, Torello Lotti, Clio Dessinioti, Angelo Massimiliano D'Erme
- Saint Louis, Catherine (2 March 2011). "Vampire Face-Lifts" Smooth at First Bite' New York Times. Retrieved 7 March 2011.
- Rehabilitation for the Postsurgical Orthopedic Patient by Lisa Maxey, Jim Magnusson page no.171
- Platelet-rich plasma: evidence to support its use. By Marx RE J Oral Maxillofac Surg. 2004 Apr; 62(4):489-96.
- osler immunopharmacology of Platelets, Edited by M. Josephpagr page no. 84
- British Journal of Haematology Volume 133, Issue 3, pages 251–258, May 2006.
- Blood Cell Morphology Grading Guide by Gene L. Gulati American Society for Clinical Pathology Press, 01-Jan-2009 - Medical - 88 pages
- Kamykowski J, Carlton P, Sehgal S, Storrie B. Quantitative immunofluorescence mapping reveals little functional coclustering of proteins within platelet alpha granules. Blood 2011;118(5):1370-1373.



Platelet-Rich Plasma: Regenerative Medicine: Sports Medicine, Orthopedic, and Recovery of Musculoskeletal Injuries
Edited by José Fábio Santos Duarte Lana, Maria Helena Andrade Santana, William Dias Belangero, Angela Cristina Malheiros Luzo

Platelet-Rich Plasma: Regenerative Medicine: Sports Medicine, Orthopedic, and Recovery of Musculoskeletal Injuries
Edited by José Fábio Santos Duarte Lana, Maria Helena Andrade Santana, William Dias Belangero, Angela Cristina Malheiros Luzo pg no 145

Rossi's Principles of Transfusion Medicine by Toby L. Simon, Jeffrey McCullough, Edward L. Snyder, Bjarte G. Solheim, Ronald G. Strauss pg. no. 228