



A RETROSPECTIVE STUDY OF COMPARISON OF OUTCOMES BETWEEN PARA-UMBILICAL AND TRANS-UMBILICAL PORT INSERTION FOR LAPAROSCOPIC SURGERIES

Dr Aditya Goyal, Dr Shashank Desai, Dr Nirav Patel

¹Third Year Resident, ²Professor and Head of the Unit, ³Assistant Professor
Department of General Surgery
GCS Medical College, Hospital and Research Centre, Ahmedabad, Gujarat
Corresponding author: Dr Aditya Goyal: Email ID – adit_1610@yahoo.co.in

Abstract

Objective: The study was undertaken to compare the intra operative feasibility, post operative pain, cosmetic results and complications between the para-umbilical and trans-umbilical techniques of laparoscopic port insertion.

Methodology: This was a comparative study carried out at a tertiary care hospital from January 2018 to January 2019. 50 patients enrolled in the study for laparoscopic surgeries were equally divided into 2 groups, Group A (25) – Para-umbilical port insertion group and Group B (25) – Trans-umbilical port insertion group.

Results: In both the groups' operation time, post-operative analgesic requirement and patient satisfaction were similar. Two cases (8%) in the para-umbilical and three cases (12%) in the Trans-umbilical group developed wound infections. The umbilical port site complications rates were comparable ($P > 0.05$).

Conclusion: The trans-umbilical incision is relatively easier to perform and has better cosmetic results and seems to be a safe and feasible alternative to the para-umbilical incision for Laparoscopic surgeries.

Keywords: Para-Umbilical Port Insertion, Trans-Umbilical Port Insertion, Laparoscopic Surgeries, Para-Umbilical, Trans-Umbilical, Laparoscopic Technique, Patient Satisfaction.

INTRODUCTION:

Laparoscopy is currently widely used in the practice of medicine, for both diagnostic and therapeutic purposes [13]. The minimally invasive approach has become the method of choice for treating abdominal diseases that require surgery. However, it is obvious that laparoscopic procedures are not risk free. Laparoscopic entry is a blind procedure, and it represents a problem for all the related complications. Complications arising from laparoscopic surgery are rare and commonly occur when attempting to gain access to the peritoneal cavity. Creation of the pneumoperitoneum is the first and most critical step of a laparoscopic procedure because that access is associated with injuries to the gastrointestinal tract and major blood vessels and at least 50% of these major complications can occur prior to commencement of the intended surgery. This complication rate has remained the same during the past 25 years.

There are two methods for creating a pneumoperitoneum, the closed technique and the open technique.

Although there is no consensus regarding the best method of gaining access to the peritoneal cavity to create a pneumoperitoneum, the Veress needle insertion (closed technique) is the most frequently used technique.

The creation of pneumoperitoneum requires a para-umbilical incision or trans-umbilical incision to introduce the needle into the abdomen. The para-umbilical incision is a commonly used method for the initial approach of the laparoscope into the abdomen [4]. It is often U-shaped placed below or above the umbilicus and it cuts through the skin, the subcutaneous fat, and the fascia.

In a review of laparoscopic practice, approximately 50% of the laparoscopists preferred the infra-umbilical route and 35.7% the supra-umbilical area for entry in peritoneal cavity.

In contrast for the trans-umbilical incision a vertical linear incision dividing the skin and fascia are needed to reach abdominal cavity. Since for trans-umbilical incision less fascial tissue needs to be separated so it is easier to perform, less traumatic and more cosmetic and thus has gained popularity [5-8].

So in this study, we going have compared the outcomes of para-umbilical and trans-umbilical port insertion techniques.



Aims and Objectives:

The retrospective case study was done on the patients undergoing laparoscopic surgeries for calculus cholecystitis, acute and sub acute appendicitis and chronic abdominal pain for following aims and objectives:

1. To study the comparison of intra operative feasibility between para-umbilical and trans-umbilical camera port site insertion in lean and obese patient.
2. To compare the incidences of postoperative pain between para-umbilical and trans-umbilical port site insertion techniques.
3. To study the cosmetic result between para-umbilical and trans-umbilical port site insertion techniques.
4. To compare the outcomes between para-umbilical and trans-umbilical port site insertion techniques regarding

Umbilical Port Site:

- Seroma/Hematoma
- Surgical site infection
- Wound dehiscence
- Incisional hernia

MATERIALS AND METHODS:

The present study is a retrospective study carried out with 50 patients at the Department of Surgery at GCS Medical College, Hospital and Research Centre, Ahmedabad between January 2018 and January 2019.

Inclusion Criteria:

- 1) Laparoscopic surgeries
- 2) Patients medically fit to undergo the procedure.

Exclusion Criteria:

1. Age < 13 years (paediatric patients) and > 80 years
2. Uncorrected coagulopathy
3. Previous laparotomy
4. Contra-indications for laparoscopic surgeries.
5. Laparoscopy converted to open surgeries

The selected patients were divided into two groups- Group A (25) - Para-umbilical port insertion.

- Group B (25) - Trans-umbilical port insertion.

Detailed history was recorded from patients and thorough clinical examination was performed. The findings were recorded in the proforma. The recorded data included demographics, multiple aims and objectives, intra operative findings and post-operative complications.

- All routine investigations were done and pre operative fitness was taken for the surgeries.

1. Surgical methods:

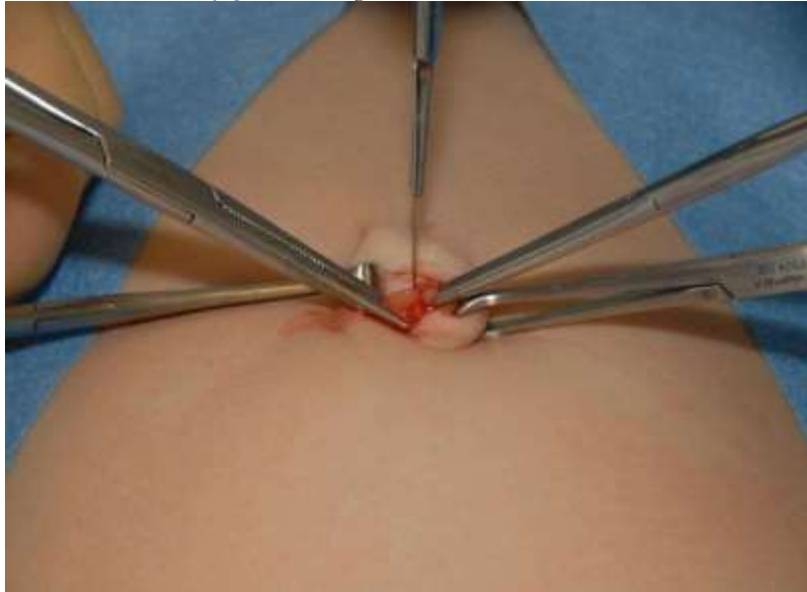- Subjects were allocated randomly in two groups according to the site of umbilical port insertion. I. Para-umbilical II. Trans-umbilical

In para-umbilical port insertion, both supra-umbilical and infra-umbilical port insertion techniques were included.

- Any case of internal organ injury related with the insertion of the umbilical trocar was recorded.
- We used 10 mm umbilical camera port in this study.
- Pre-operative preparation:
 - All patients received antibiotics intravenously at the induction of anaesthesia as per hospital protocol.
 - In all patients, the umbilicus was cleaned thoroughly preoperatively with spirit swabs. Intraoperative routine manual cleaning was also performed in both the para-umbilical and trans-umbilical groups.
 - After cleaning the umbilicus intraoperatively, skin preparation was done in both the groups using 10% betadine.
- Operative method:
 - In trans-umbilical group, a midline vertical incision was made through the umbilicus. With slight retraction of the skin on both sides of the umbilicus using tissue forceps the fascia lying underneath the umbilicus was visualized and with further dissection the peritoneal cavity was easily entered either by open (Hasson's) method or by closed (Veress) method.



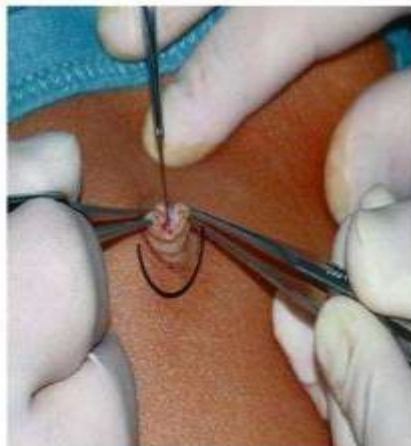- Post-surgery, fascia closed by vicryl port closure 2-0 in U-manner and skin closed with ethilon 2-0 in simple interrupted manner. A piece of rounded dry gauze was placed in the umbilicus and adhesive bandage was applied.



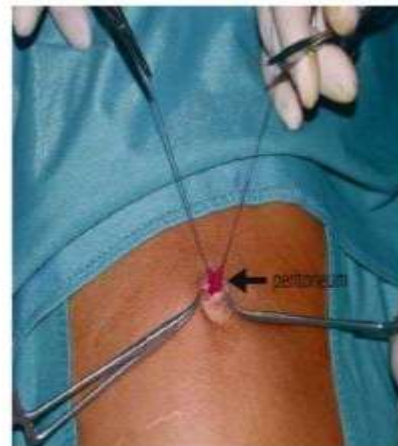
Vertical incision kept over umbilicus after everting it.

- Whereas in para-umbilical group, a transverse incision above or below the umbilicus was made over the skin crease. The subcutaneous fat was dissected, and the exposed fascia was opened. After opening of the fascia, either direct trocar insertion or insertion after insufflation with a Veress needle was done.
 - Post-surgery, fascia closed by vicryl port closure 2-0 in U-manner and skin closed with ethilon 2-0 in simple interrupted manner. A piece of rounded dry gauze was placed in the umbilicus and adhesive bandage was applied.
- Infraumbilical

Techniques of peritoneal entry



Verrese needle (classical technique)
through infraumbilical incision

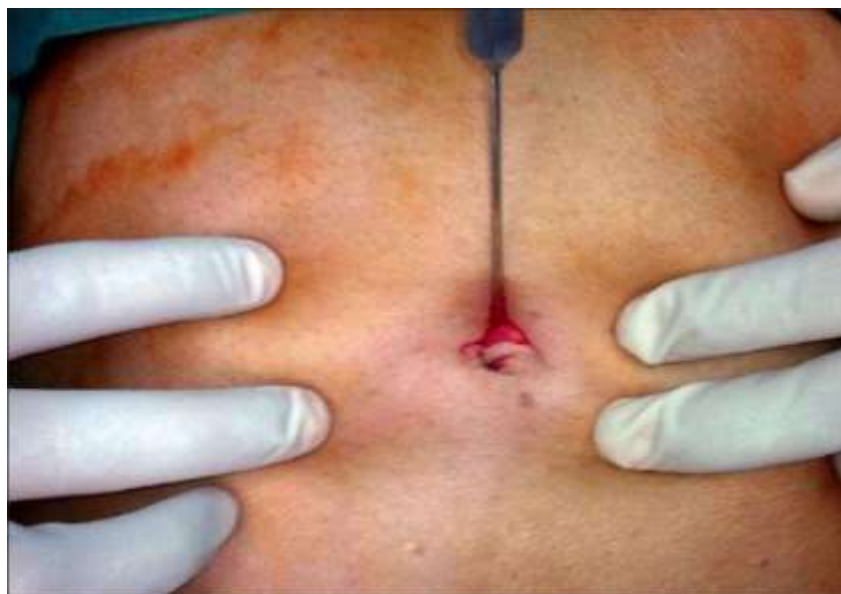

Open (Hasson technique)

By M.A Wadood, MD, MRCS

Transverse or U shaped incision kept at the inferior border of umbilicus

Supraumbilical



Transverse incision kept at superior border of umbilicus

- Post-operative care and follow up:
All patients were treated with post-operative:
 1. Nil by mouth for 6 hours
 2. TPRBP 6 hourly
 3. Mobilisation from the day of operation
 4. Intravenous antibiotics
 5. Analgesics for pain
 6. Wound dressing when required
- Patients were observed in surgical ward postoperatively and every 24 hourly wound was inspected for any signs of wound infection and dressing was done when required. Patients were discharged as per hospital protocol and asked to come for review at the outpatient department after 7 days or early if they had any wound discharge.
- All patients underwent regular dressing and stitches were removed on POD-10.
- All patients were followed up after discharge at regular intervals for 3 months and were clinically assessed for postoperative pain, port site seroma/hematoma, surgical site infection, wound dehiscence, postoperative scar and port site hernia.

- Post-operative pain has been documented according to the pain scale.
- Post-operative scar has been described as mature scar and hypertrophic scar.

Mature scar: it is light coloured and flat scar without redness and raised tissue.

Hypertrophic scar: it is red, raised and sometimes itchy scar developed within weeks of surgery.

Statistical Methods

Mean, standard deviation was used as descriptive statistics. For Inferential statistics Chi-square test, Fisher's exact test, student t test were used.

OBSERVATIONS AND RESULTS:

The mean age of patients in Group A: Para-Umbilical group was 40.26 ± 12 years (Range from 13-80 years) and Group B: Trans-Umbilical group was 41.04 ± 15 years (Range from 13-80 years).

Majority of the patients in both groups did not have any co-morbidity. In Group A (Para-Umbilical), 3 patients had hypertension and 1 had diabetes (16%). In Group B (Trans-Umbilical), 2 patients had hypertension and 3 had diabetes (20%). There was no patient with COPD in either group.

In group A there were 12 males (48%) and 13 females (52%) and in group B there were 11 males (44%) and 14 females (56%).

(Table 1) Comparison of Port Insertion Time (Minutes) Between the Group A and Group B

Duration of Time (Min)	Group A		Group B	
	N	%	N	%



1-5	15	60	19	76
5-10	8	32	4	16
10-15	2	08	2	8
Total	25	100%	25	100%

Port insertion time in our study is as follows (it was calculated from time of incision till the insertion of 10mm port).

(Table 2) Port insertion time is almost comparable for both Para- Umbilical (Group-A) and Trans- Umbilical (Group- B).

Port Insertion Time	Group A(25)	Group B(25)	P Value
Average Duration	4.9 mins \pm 2.9	4.1 mins \pm 2.4	0.2933
	Port insertion time is almost same for both the groups and statistically not significant.		

(Table 3) Laparoscopic surgeries done in each group

In group A out of the total patients 14 underwent Laparoscopic Appendicectomy, 10 underwent Laparoscopic Cholecystectomy and 1 underwent Diagnostic Laparoscopy whereas in group B the numbers were 12, 11 and 2 respectively.

Name of the Surgery	Para-Umbilical Group(25)	Trans-Umbilical Group (25)
Lap. Appendicectomy	14(56%)	12(48%)
Lap. Cholecystectomy	10(40%)	11(44%)
Diagnostic Lap.	1(4%)	2(8%)

(Table 4) Complications

Port Site complications observed in our study were as follows:		
Complications	Para-Umbilical	Trans-Umbilical
Seroma	1	0
Hematoma	0	0
Infection	2	3
Wound Dehiscence	0	0
Incisional Hernia	1	0

There were 4 patients with complications in para-umbilical group (16%). There were 3 patients with complications in trans-umbilical group (12%). Incidence of complications were more in Para-Umbilical Group, with $p=0.4249$ thus statistically not significant.

(Table 5) Post-operative PAIN

Pain score according to VAS	Group A			Group B		
	Day 1	Day 2	DOD	Day 1	Day 2	DOD
No Pain	0	0	23	0	0	22
Mild Pain	15	20	2	16	18	3
Moderate Pain	8	5	0	6	7	0
Severe Pain	2	0	0	3	0	0

There was no statistically significant difference between two groups of patients on day 2, ($p=0.7416$) and on DOD ($p=0.6743$).

(Table 6) Patients Satisfaction (For Scar Mark In Post Operative Period)

Satisfaction	Para-Umbilical (n=25)	Trans-Umbilical (n=25)
Strongly disagree	0	0



Disagree	0	0
Undecided	1	1
Agree	6	2
Strongly agree	18	22

18 patients (72%) in Group A and 22 patients (88%) in group B were completely satisfied with the scar results. (Table 6)

DISCUSSION

Since the beginning of laparoscopic surgeries, continuous efforts have been made for better cosmetic results. Chow et al. [5] reported a method of SILS performed through an intraumbilical incision. This method left virtually no scar after surgery. Vidal et al. [9] reported a type of single-incision laparoscopic surgery performed with a suprapubic approach. Because of the pubic hair covering the low-lying incision, cosmetic results were remarkable. In spite of these newer advances the para-umbilical incision for laparoscopy is still being widely used in our country. Lee et al. [10] reported that single incision laparoscopic appendectomy performed with an trans-umbilical incision had lower incidence of complications compared to open appendectomy and that infection rates were actually lower in the single incision group. The latest development in this field of “scarless” surgery is Natural Orifice Transluminal Endoscopic Surgery (notes) where surgery is performed with an endoscope passed through a natural orifice (mouth, urethra, anus, etc.) and then through an internal incision in the stomach, vagina, bladder, colon, thus avoiding any external incision or scar. In our study, the wound complication rates of the para-umbilical and trans-umbilical approach did not show any significant difference. Wound infection was observed for 3(12%) patients in the trans-umbilical group and 2(8%) patients in the para-umbilical group which is comparable to study done by Rajkhowa et al [13]. All the patients were followed up at the outpatient clinic 7 days after discharge. Of the 25 patients in the paraumbilical group, 1 patient experienced mild serous wound discharge and 1 patient developed incisional hernia but no such complication was seen in trans-umbilical group which is comparable to the study done by Jun Suh Lee et al [12]. All our study patients had complete healing of the laparoscopy wound within 30 days. The lower incidence of complication observed in the trans-umbilical incision could be because in this approach there is less potential space for seroma or hematoma to form, which mainly leads to postoperative wound infection. The para-umbilical incision on the other hand leaves an obvious scar close to the umbilicus, where healing may not always take place perfectly [8]. For the trans-umbilical incision, the entire incision is contained within the umbilical ring which itself contains many skin folds making the scar virtually invisible [8]. The trans-umbilical incision is easy to perform as the fascia lies directly beneath the umbilical skin with virtually no subcutaneous fat hence the peritoneal cavity is entered with minimal dissection. Second, the close proximity of the layers also allows for a much faster closure of a trans-umbilical wound. In most of our patients, a single full layer suture was sufficient for port closure. In comparison, the para-umbilical incision needed a more laborious process of closure as the fascia, subcutaneous fat and skin all had to be separately closed. In the case of an obese patient with a thick layer of subcutaneous fat, the opening and closure of the para-umbilical trocar site is often quite difficult [8, 11]. In contrast by using the trans-umbilical approach and with lateral retraction of the skin on both sides of the umbilicus, the umbilical ring is easily exposed in even obese patients [11]. All types of laparoscopic surgeries may benefit from applying the trans-umbilical incision [8, 11]. This study was somewhat limited in that it was a retrospective study and effects of systemic disease on the wound healing, such as perioperative glycemic status and body oxygen levels were not assessed.

CONCLUSION

The Trans-Umbilical incision is a safe and feasible alternative for the Para-Umbilical incision. Our results have shown that despite the widespread belief that a Trans-Umbilical incision will cause more wound infection actual wound complication rates are lower compared with Para-Umbilical incision. Also it is easier to perform the TransUmbilical incision and it also has a better cosmetic outcome than Para-Umbilical incision.

ACKNOWLEDGEMENTS: none

CONFLICTS OF INTEREST: none

FUNDING: Nil



REFERENCES

- Sauerland S, Jaschinski T, Neugebauer EA. Laparoscopic versus open surgery for suspected appendicitis. *Cochrane Database Syst Rev* 2010; 10:CD001546.
- Holder-Murray J, Zoccali M, Hurst RD, Umanskiy K, Rubin M, Fichera A. Totally laparoscopic total proctocolectomy: A safe alternative to open surgery in inflammatory bowel disease. *Inflamm Bowel Dis* 2012; 18:863-8.
- Pearce NW, Di Fabio F, Teng MJ, Syed S, Primrose JN, Abu Hilal M. Laparoscopic right hepatectomy: A challenging, but feasible, safe and efficient procedure. *Am J Surg* 2011; 202:e52-8.
- Zollinger RM, Ellison EC, Zollinger RM. *Zollinger's Atlas of Surgical Operations*. 9th ed. New York: McGrawHill Medical; 2011.
- Chow A, Purkayastha S, Nehme J, Darzi LA, Paraskeva P. Single incision laparoscopic surgery for appendectomy: a retrospective comparative analysis. *Surg Endosc* 2010; 24:2567-74.
- Kim HJ, Lee JI, Lee YS, Lee IK, Park JH, Lee SK, et al. Single-port transumbilical laparoscopic appendectomy: 43 consecutive cases. *Surg Endosc* 2010; 24:2765-9.
- Piskun G, Rajpal S. Transumbilical laparoscopic cholecystectomy utilizes no incisions outside the umbilicus. *J Laparoendosc Adv Surg Tech A* 1999;9:361-4.
- Lee JS, Hong TH, Kim JG. A comparison of the periumbilical incision and the intraumbilical incision in laparoscopic appendectomy. *J Korean Surg Soc* 2012;83:360-6.
- Vidal O, Ginestà C, Valentini M, Martí J, Benarroch G, García-Valdecas Suprapubic single-incision laparoscopic appendectomy: A nonvisible-scar surgical option. *Surg Endosc* 2011;25:1019-23.
- Lee SY, Lee HM, Hsieh CS, Chuang JH. Transumbilical laparoscopic appendectomy for acute appendicitis: A reliable one-port procedure. *Surg Endosc* 2011;25:1115-20.
- Iranmanesh P, Morel P, Inan I, Hagen M. Choosing the cosmetically superior laparoscopic access to the abdomen: The importance of the umbilicus. *Surg Endosc* 2011; 25:2578-85.
- Jun Suh Lee, Tae Ho Hong, Jun Gi Kim A comparison of the periumbilical incision and the intraumbilical incision in laparoscopic appendectomy *J Korean Surg Soc* 2012;83:360-366
- Rajkhowa K, Gogoi M, Baruah I. Periumbilical Incision Versus Intraumbilical Incision for Laparoscopic Appendectomy: A Randomized Comparative Study. *Int J Sci Stud* 2016;4(8):172-175.